

# Application of functional orthodontic appliances to treatment of “mandibular retrusion syndrome” —Effective use of the TRAINER System™—

Akira KANAO <sup>1)</sup>, Masanori MASHIKO <sup>2)</sup>, Kosho KANAO <sup>3)</sup>

1) Department of Behavioral Pediatric Dentistry, Okayama University Graduate School of Medicine, Dentistry and Pharmaceutical Sciences

2),3) Kanao Dental Clinic

## Introduction

There have recently been an increasing number of parents complaining of their children's health-related problems other than caries, such as decline in exercise ability, open-mouth posture, slow eating, allergy and misaligned teeth. Indeed, studies have shown increases in the number of children with difficulty masticating hard chewy food or inability to swallow correctly<sup>1,2)</sup>. The decline in oral function is attributed to dietary changes among children in the modern Japanese society including the eating of soft foods at home and elsewhere<sup>3,4)</sup>. It has also been shown that the perioral muscles in growing children influence body posture, respiration, mastication, deglutition, speech and morphology of the jaws and teeth<sup>5,6)</sup>.

When it is difficult to breathe through the nose due to, for example, tonsillitis or allergic rhinitis, habitual mouth-breathing is inevitable. Mouth breathing has been shown to adversely affect the morphology of the dental arch and jaw bones<sup>7)</sup>. It causes dryness of oral and pharyngeal mucosa. Dry mucosa is more sensitive and susceptible to inflammation. Inflamed mucosa is more vulnerable to bacterial infection, which in turn aggravates the inflammatory condition. The pharynx gets swollen when

inflamed, making the airway narrower. Airway constriction increases breathing difficulty, which induces mouth breathing further. Pharyngeal inflammation caused by mouth breathing spreads to the tonsils. The tonsils have an immunoprotective function, but become a source of infection once infected<sup>8)</sup>. Infected tonsils cause further narrowing of the upper and lower airways. Mouth breathing habit thus has negative impact, particularly on the morphology of the jaws and dental arches in growing children. The morphology of the jaws and dental arches then begins to control function, perpetuating a downward or negative spiral of vicious circle.

Pediatric dentists are in a better position to discover this downward spiral through the dental health checkup system they have established and promoted, which will give them a chance not only to help children with dental problems but to collaborate with otorhinolaryngologists, pediatricians and other specialists.

## Maxillary protrusion

In our previous paper, we reported on “mandibular retrusion syndrome” in mandibular protrusion cases<sup>9)</sup>. Maxillary protrusion can be classified into three main skeletal types; 1)

## FEATURE: Maxillary protrusion

overdeveloped maxilla, 2) underdeveloped mandible, 3) combination of the two.

Nezu, et al.<sup>10,11)</sup> showed in their studies assessing anteroposterior relationship of the maxilla and mandible relative to Nasion-perpendicular (McNamara Line) that a great majority or 73% of Japanese Class II malocclusions were associated with mandibular retrusion while true maxillary protrusion (overdeveloped maxilla) accounted for only 7%. In our view, etiologies of maxillary protrusion due to mandibular retrusion include myofunctional habits during infancy and early childhood, e.g., thumb/finger sucking, pacifier use and the way babies are breast-fed.

This case in the primary dentition had a large overjet causing lip incompetence (Fig. 1). Without good lip seal, he had to build negative intraoral pressure for swallowing by curling the lower lip under the upper anterior teeth. Lip incompetence leads to further

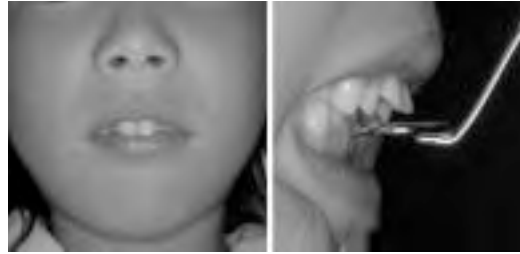

Fig. 1 Maxillary protrusion aggravated by myofunctional habits

deformation of the jaws and dental arches, making lip closure even more difficult. He also exhibited marked mentalis and buccinators strain during swallowing. The inward force exerted by the buccinators causes constriction of the upper and lower dental arches into a V shape and pressure from the strained mentalis muscle pushes the mandible down and back. This clockwise rotation of the mandible can be a cause of airway constriction, giving rise to the above-mentioned nega-

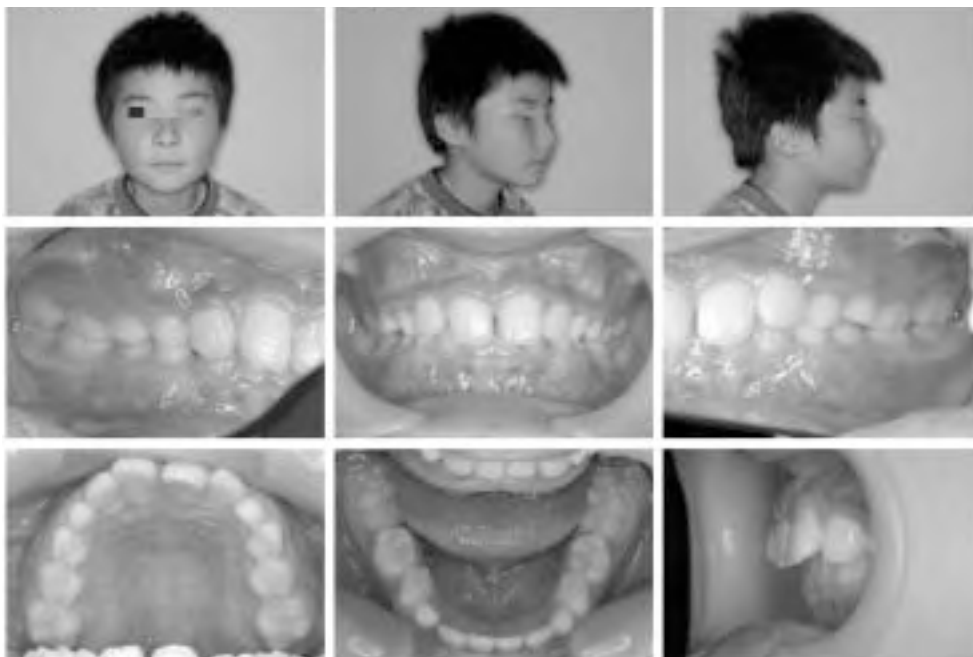

Fig. 2 Before Phase I treatment with Bionator (age 10Y8M)

4) Application of functional orthodontic appliances to treatment of "mandibular retrusion syndrome"

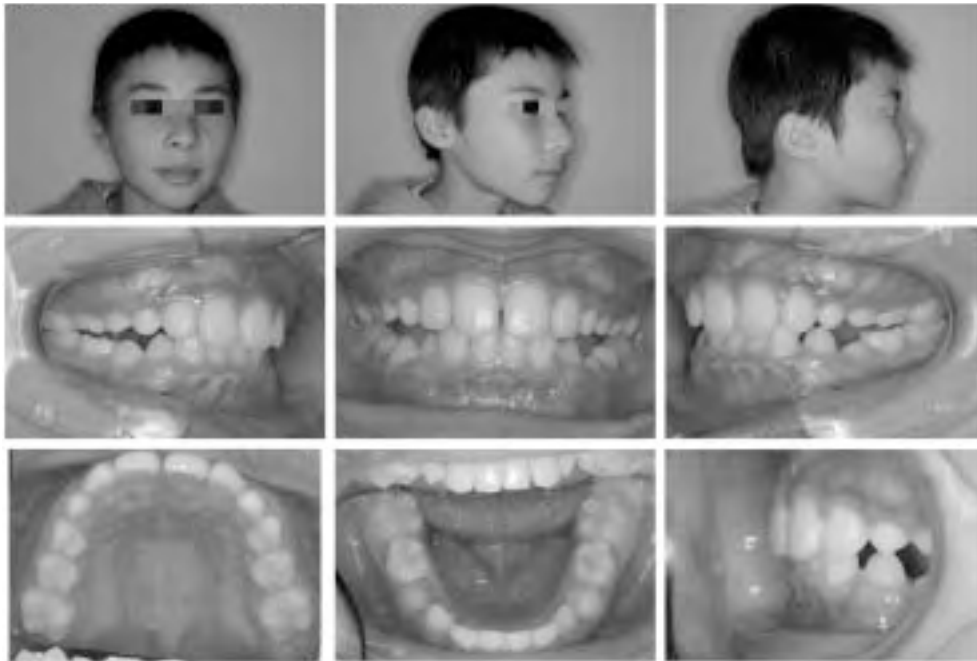

Fig. 3 After Phase I treatment with 1 year and 1 month of Bionator (age 11Y9M)

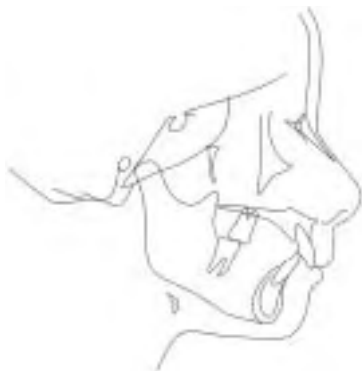

Fig. 4 Before Phase I (age 10Y8M)



Fig. 5 End of Phase I treatment (age 11Y9M)

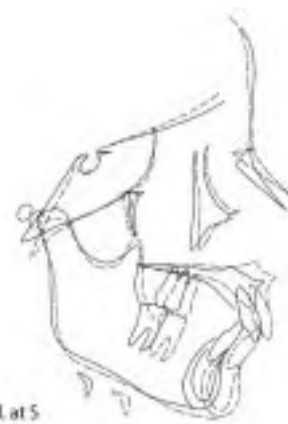

Fig. 6 Changes after 1 year and 1 month of treatment

tive spiral.

In our clinic, we have been using appliances that are optimal for Phase I treatment of maxillary protrusion, such as bite plane, Bionator and Twin Bock, and found these appliances very effective. Fig. 2 to 8 shows a case treated with Bionator.

This patient had an overjet of +6mm and overbite of +6mm with ANB of 10.3° and FMA of 21.9°. He was diagnosed as having a Class I division 1 malocclusion with a normal maxilla and a retrusive mandible. Bionator was used to stimulate forward mandibular growth in Phase I. The patient's good compliance

## FEATURE: Maxillary protrusion

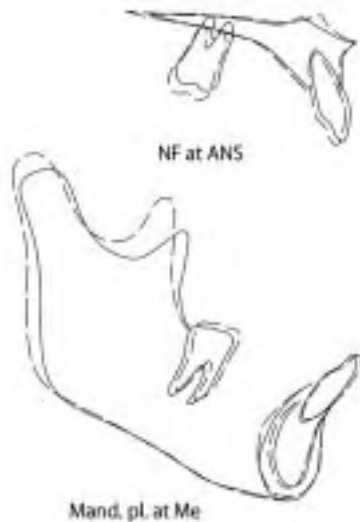

Fig. 7 Maxillary and mandibular changes

Fig. 8 Cephalometric changes

A case treated with Bionator	Before Phase I treatment age 10Y8M	After Phase I treatment age 11Y9M
SNA	88.0°	90.0°
SNB	77.7°	80.6°
ANB	10.3°	9.4°
Mand.Plane	21.9°	25.7°
U-1 to FH plane	108.0°	103.9°
L-1 to Mand. Plane	106.9°	104.6°
Facial axis	88.5°	89.7°
A'-ptm'	51.6mm	54.3mm
Gn-Cd	107.5mm	113.5mm
Pog'-Go	73.5mm	77.1mm
Gd-Go	54.2mm	53.8mm

allowed for full effect of the appliance. There was adequate improvement in anterior coupling to an overjet of +2mm and overbite of +2mm at the end of Phase I treatment. Cephalometric analysis demonstrated a tendency for improvement in ANB (9.4°) and FMA (25.7°).

Bionator is a functional appliance developed by Balter<sup>12)</sup> in the 1950's. It is a mono-block

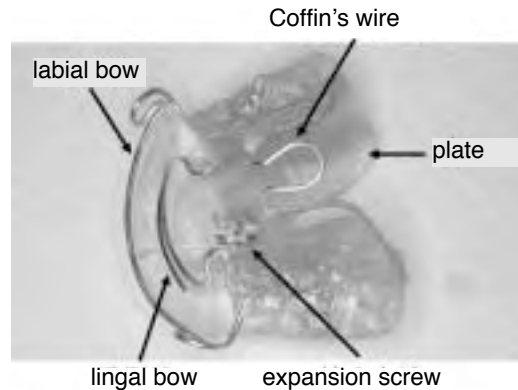


Fig. 9 Bionator used

appliance with the upper and lower parts integrated into one unit, comprising resin, wires and an expansion screw. It is mainly used for treatment of maxillary protrusion. A construction bite is taken with the mandible brought forward to an edge-to-edge position. The appliance has the effects of increasing the intraoral volume and facilitating lip seal.

In our clinic, Bionators were previously used in children at Hellman's dental age IIC to IIIB. The appliance had to be frequently adjusted by grinding or adding resin due to such problems as mobility of exfoliating primary teeth and ectopic eruption of successive permanent teeth. This increased chairtime and the appliance adjustment was sometimes very difficult to make. In our search for optimal appliances by trial and error, we were introduced to the TRAINER System™ in 2000. The TRAINER System™ lineup includes the T4K™ (TRAINER for Kids), T4A™ (TRAINER for Alignment), T4B™ (TRAINER for Braces) and T4CII™ (TRAINER for Class II). The T4K™ is further divided into two types, soft and harder. **Although we were initially puzzled by the wide range of appliances available in the product lineup, appliance selection is simple and straightforward.** The

T4K™ is the appliance of choice when the second molars are still unerupted. The T4A™ or T4CII™ is selected thereafter. The T4B™, which is designed to be used with braces, tends to increase patient susceptibility to stomatitis. The T4B™ can be used as a retainer to maintain mandibular position after insufficient Phase I treatment.

When we first incorporated the TRAINER System™ into our practice, we used it for bite opening prior to multi-bracket appliance therapy. We later observed added benefits of the system in eliminating minor crowding and improving Class II relationship in many cases. Some parents were satisfied with the improvements obtained with the TRAINER System™ and declined further treatment, giving us mixed feelings. In fact, the number of patients treated with multi-bracket appliances in our clinic decreased after the introduction of the TRAINER System™. The next section will describe the effectiveness of the T4K™ in Phase I treatment.

#### Features and objectives of the TRAINER System™

The TRAINER System™ appliances were designed and developed as a functional appliance system through repeated refinements over a period of 10 years to arrive at the current stable design. These appliances were devised to improve muscle function. They were approved as orthodontic appliances by the Japanese regulatory authority in 2008 (Fig. 10).

The TRAINER System™ appliances look similar to a positioner. The latter is fabricated on setup models and allows some tooth movement. The positioner is more like a bite block made of elastic resin and designed to settle teeth and occlusion to predetermined, setup positions. In contrast, the TRAINER System™

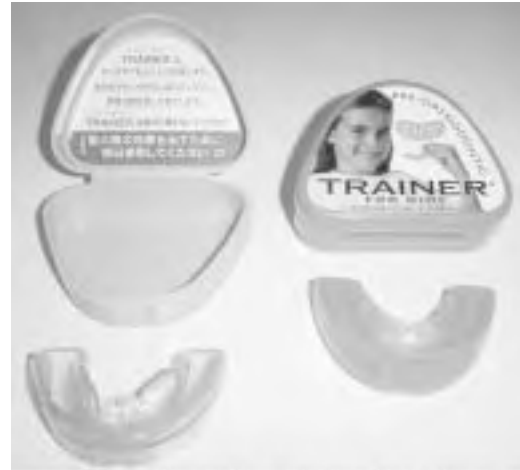

Fig. 10 Soft type made of silicone (left), harder type made of polyurethane (right)

appliances are designed not only to improve form but to harmonize form and function.

#### Structure of the TRAINER System™ appliance

The TRAINER System™ appliance is a flexible appliance made of non-thermoplastic silicone (soft) or polyurethane (harder) (Fig. 11). It is used to improve oral function. Treatment is initiated with the soft type, followed by the harder type. The appliance has two main effects, one to guide hard tissues, i.e. jaws and dental arches, and the other to guide soft tissues, i.e. perioral muscles.

#### <Hard-tissue guidance system>

The TRAINER System™ appliance brings the mandible forward using the upper anterior teeth as an anchorage source. It also has an arch-expansion effect on a constricted arch, creating room for tooth alignment. Thus, mild crowding may be eliminated with proper use of the appliance.

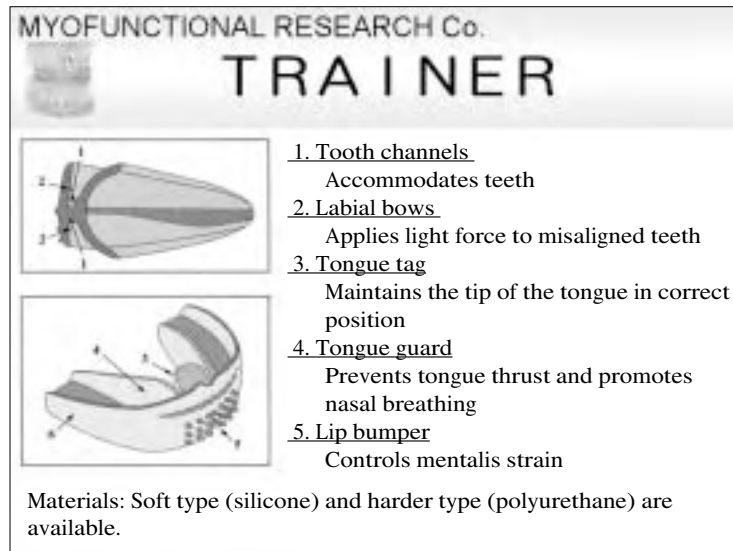


Fig. 11 Structure of T4K™

<Soft-tissue guidance system>

Patients with maxillary protrusion and mandibular retrusion often show mentalis strain. The TRAINER System™ appliance positions the mandible forward as a hard-tissue guidance system, facilitating lip seal and nasal breathing. This effect is unique to mono-block appliances. The appliance also promotes proper functioning of the perioral muscles that are involved in abnormal swallowing with the lower lip caught behind the upper anterior teeth or tongue-thrust swallowing. This helps to widen the lower airway.

**Target ages and uses  
of the TRAINER System™**

The objective of orthodontic treatment is to achieve maximum effect with minimum necessary treatment. Functional appliances including the TRAINER System™ should be used during active growth. There are large gender and individual variations in the timing of growth peak. Scammon's growth curves indicate that maxillary growth is similar to neural

growth and mandibular growth to general growth. This means that treatment timing varies greatly depending on the type of malocclusion (Fig. 12).

The instruction manual of the TRAINER System™ recommends the age ranges in which each appliance can be used effectively; 2 to 5 years for INFANT TRAINER™, 6 to 12 years for the T4K™ and over 12 years for the T4A™. Because of individual variations in growth, age limits vary from one patient to another. Our patients are instructed to wear the TRAINER appliance for around 2 hours during the day and at night during sleep depending on the child's age.

In our office, the use of the T4K™ is initiated when the child is at Hellman's dental age IIC or older rather than at a given calendar age. Therapy with the T4K™ should be started with 30 minutes to 1 hour of daytime wear of the soft type. When the patient is accustomed to the soft-type appliance after one month of use, wear time is increased from 1 hour to 1.5 and then to 2 hours. Nighttime

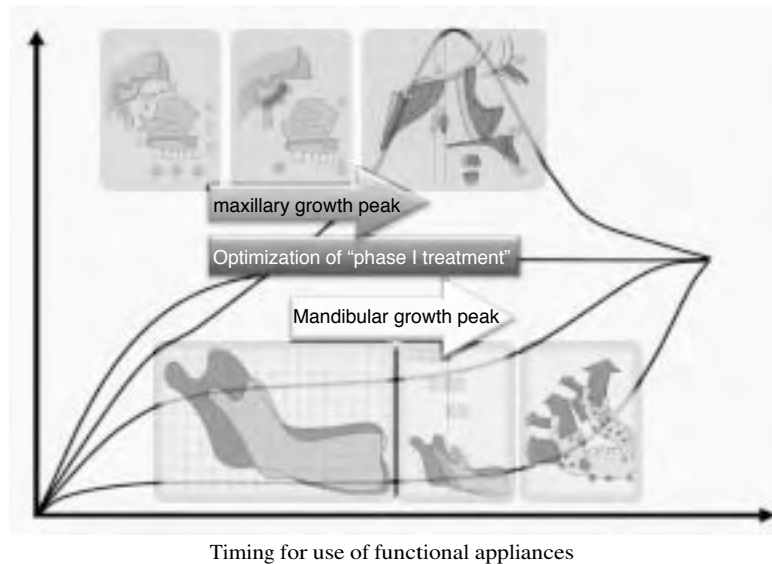


Fig. 12 Optimal timing for Phase I treatment

wear is finally added. Patient information is gathered before treatment using the assessment chart introduced in our previous article. At every monthly visit, the patient is asked how much time he wore it during the previous one month.

#### Case presentation

<Case 1 S.N. > (Fig. 13-20)

**Diagnosis:** An 8-year-old girl presented with protruded anterior teeth. Facial photographs showed a retrusive mandible, a protrusive maxilla, an everted lower lip and mentalis strain. Intraorally, E/E terminal plane was of distal step type bilaterally. The upper anterior teeth were protrusive with an overjet of +6mm and overbite of +3mm. Cephalometric analysis showed retrusion of B-point, ANB of 6.8° and FMA of 31.0°. Based on these initial records, she was diagnosed as having a Class II division 1 malocclusion.

—End of Phase I treatment: 2 years and 10 months of treatment time

At the end of Phase I treatment with the T4K™, both the patient and parents felt that the face no longer looked protrusive. Her post-treatment facial photographs show improvements in mandibular retrusion, upper lip protrusion, lower lip curl and mentalis strain. Intraorally, the molar relationship remained Class I on the left side and Class II on the right side. Both overjet and overbite were reduced to +2mm. Cephalometrically, ANB was improved to 5.1° with a slightly increased but favorable FMA of 33.2°. Comparison of pre- and post-treatment models showed an increase of 3mm in upper inter-premolar width.

**FEATURE: Maxillary protrusion**

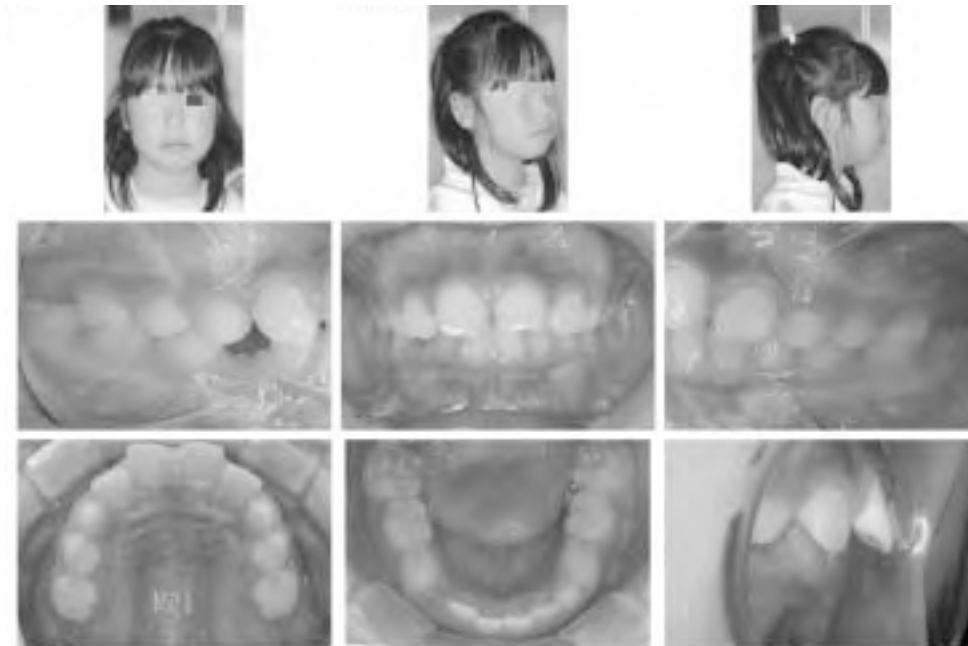


Fig. 13 Before Phase I treatment with T4K™ (age 8Y0M)

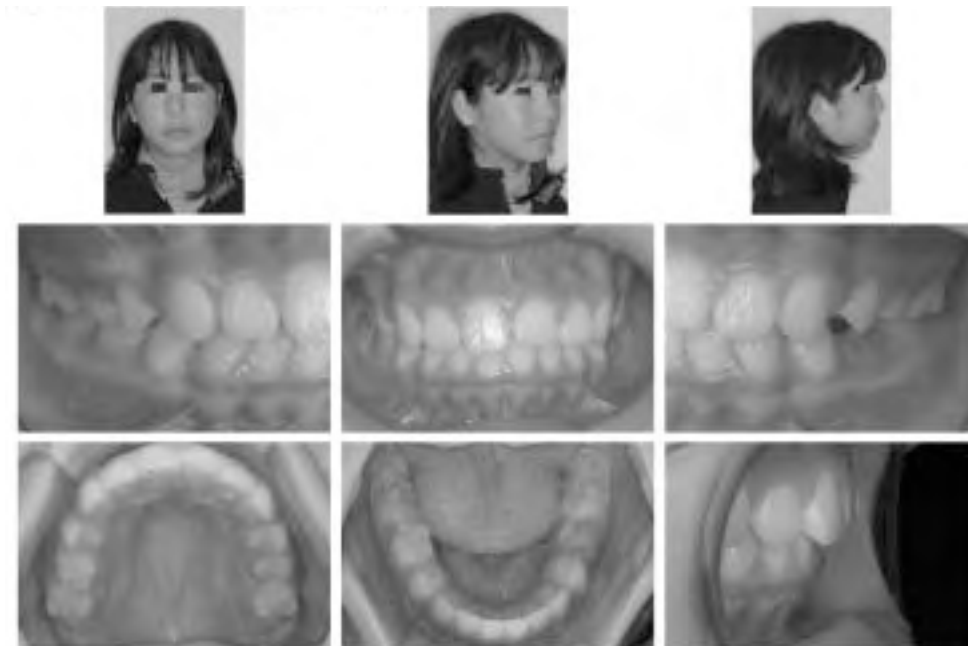

Fig. 14 After Phase I treatment with 2 years and 10 months of T4K™ (age 10Y10M)



4) Application of functional orthodontic appliances to treatment of "mandibular retrusion syndrome"

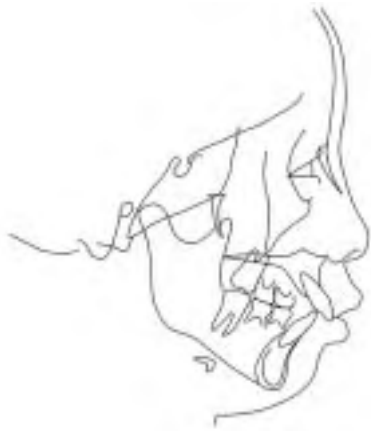

Fig. 15 Before Phase I (age 8Y0M)

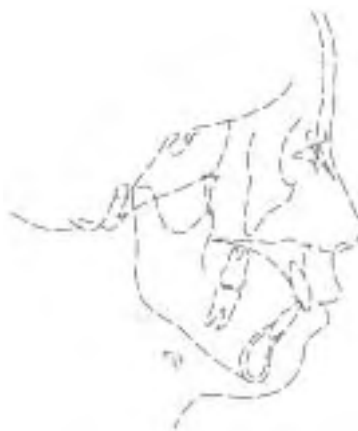

Fig. 16 After Phase I (age 10Y10M)

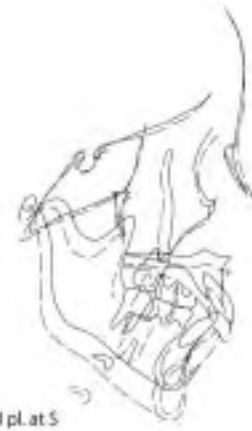

Fig. 17 Changes after 2 years and 10 months of treatment

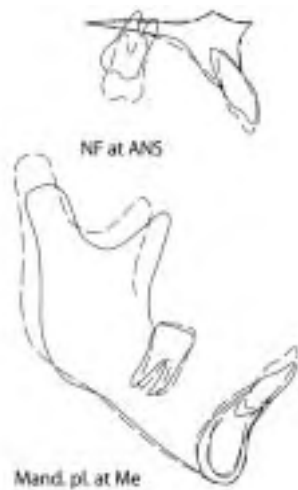


Fig. 18 Maxillary and mandibular changes

Fig. 19 Cephalometric changes

Case 1	Before Phase I treatment age 8Y0M	After Phase I treatment age 10Y10M
SNA	78.3°	77.9°
SNB	71.5°	72.8°
ANB	6.8°	5.1°
Mand.Plane	31.1°	34.6°
U-1 to FH plane	119.8°	106.8°
L-1 to Mand. Plane	105.3°	94.4°
Facial axis	84.6°	81.0°
A'-ptm'	45.4mm	47.4mm
Gn-Cd	106.0mm	115.2mm
Pog'-Go	67.7mm	72.9mm
Gd-Go	50.9mm	57.0mm

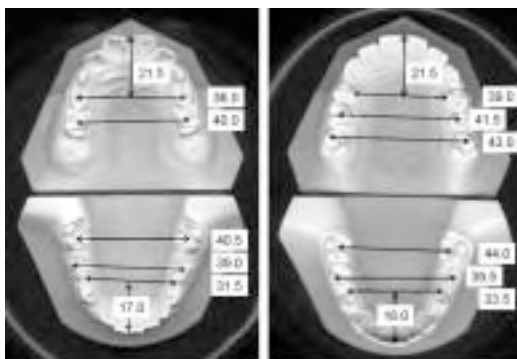


Fig. 20 Changes in upper and lower dental arches

<Case 2 M.Y. > (Fig. 21-28)

**Diagnosis:** The patient was a half-Japanese half-Caucasian girl aged 7 years 8 months with chief complaints of deep bite and lack of lower incisor display. Facially, a low-angle tendency was noted. Molar relationship was Class II on both sides. The upper anterior teeth were protrusive with an overbite of +6mm and overbite of +5mm. Cephalometric analysis showed retruded B-point, ANB of 6.2°

**FEATURE: Maxillary protrusion**

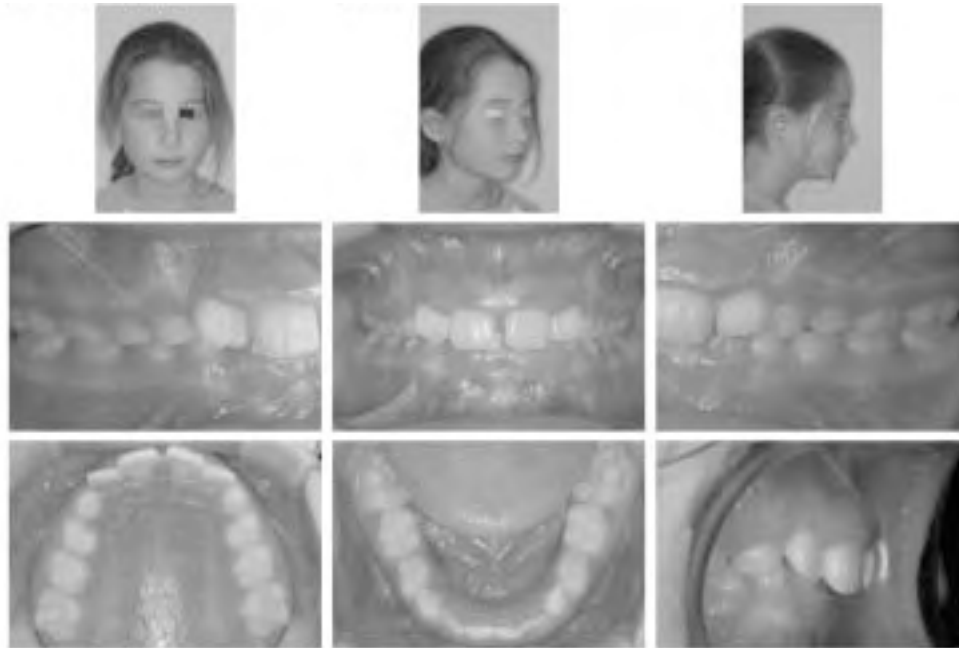


Fig. 21 Before Phase I treatment with T4K™ (age 7Y8M)

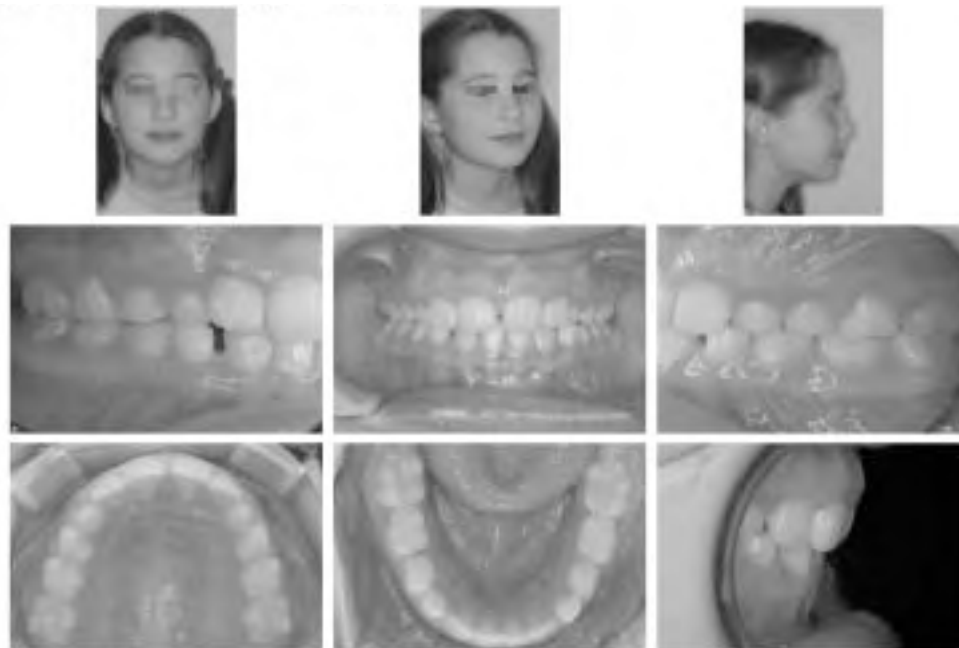

Fig. 22 After Phase I treatment with 1 year and 1 month of T4K™ (age 8Y9M)

4) Application of functional orthodontic appliances to treatment of "mandibular retrusion syndrome"

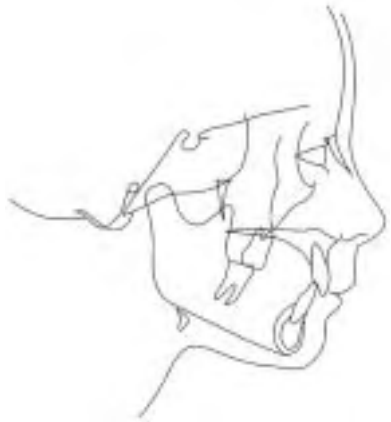

Fig. 23 Before Phase I (age 7Y8M)

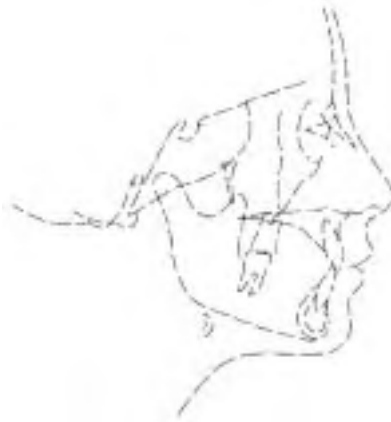

Fig. 24 After Phase I (age 8Y9M)

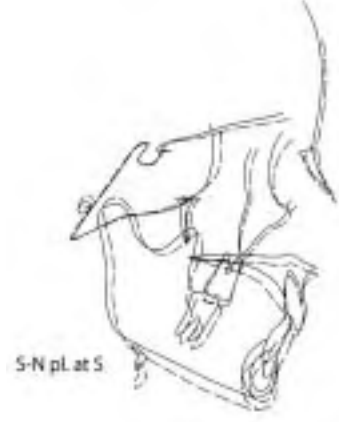

Fig. 25 Changes after 1 year and 1 month of treatment

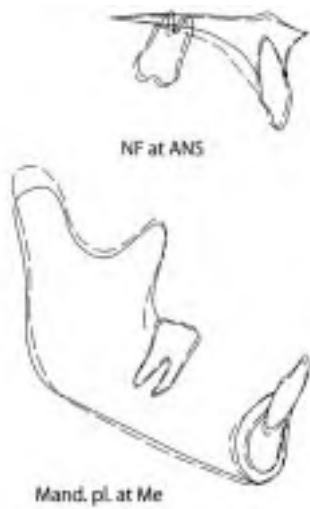

Fig. 26 Maxillary and mandibular changes

Fig. 27 Cephalometric changes

Case 2	Before Phase I treatment age 7Y8M	After Phase I treatment age 8Y9M
SNA	84.0°	83.0°
SNB	77.8°	78.7°
ANB	6.2°	4.3°
Mand.Plane	22.5°	19.9°
U-1 to FH plane	100.6°	99.5°
L-1 to Mand. Plane	95.0°	93.8°
Facial axis	92.1°	90.9°
A'-ptm'	52.1mm	52.7mm
Gn-Cd	106.7mm	113.3mm
Pog'-Go	71.8mm	77.8mm
Gd-Go	54.8mm	53.9mm

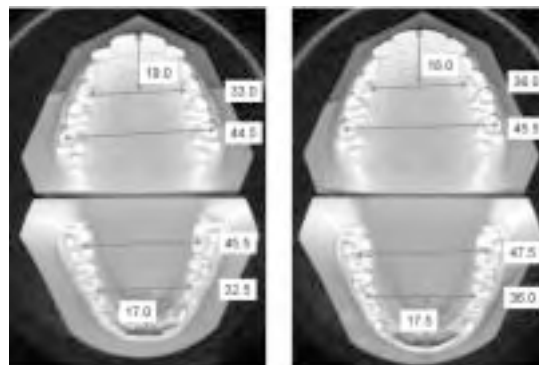


Fig. 28 Changes in upper and lower dental arches

## FEATURE: Maxillary protrusion

and FRMA of 22.5°. Thus, the case was diagnosed as Class II division 1.

—End of Phase I treatment: 1 year and 1 month of treatment time

At the end of Phase I treatment with the T4K™, the patient and parents were happy with good tooth alignment. Retrognathic appearance was improved as the upper lip protrusion, lower lip curl and mentalis strain were eliminated. Molar relationship was corrected to Class I. The overjet and overbite were reduced to +1.5mm and +2mm, respectively. ANB and FMA were improved to 4.3° and 19.9°, respectively. There was an increase of 3mm in upper inter-premolar width when pre- and post-treatment models were compared.

<Case 3 W.K.> (Fig. 29-36)

**Diagnosis:** A 9-year-9-month girl came in with protruded anterior teeth. Facially,

mandibular retrusion, upper lip protrusion, lower lip curl and mentalis strain were noted. Intraorally, molar relationship was Class II on both sides. The upper anterior teeth appeared protrusive with an overjet of +6mm and overbite of +4mm. Frenum surgery was necessary to release tongue-tie. Cephalometric analysis showed retruded B-point, ANB of 5.6° and FMA of 20.1°. The patient was diagnosed as having a Class II division 1 malocclusion.

—End of Phase I: 1 year and 5 months of treatment time

After Phase I treatment with the T4K™, the patient and parents no longer felt that the teeth were protruded. Favorable facial changes were observed with improvement of mandibular retrusion and elimination of upper lip protrusion, lower lip curl and mentalis strain. Molar relationship was corrected to Class I on both sides. Both overjet and overbite were reduced to +1.0mm. Lingual frenec-

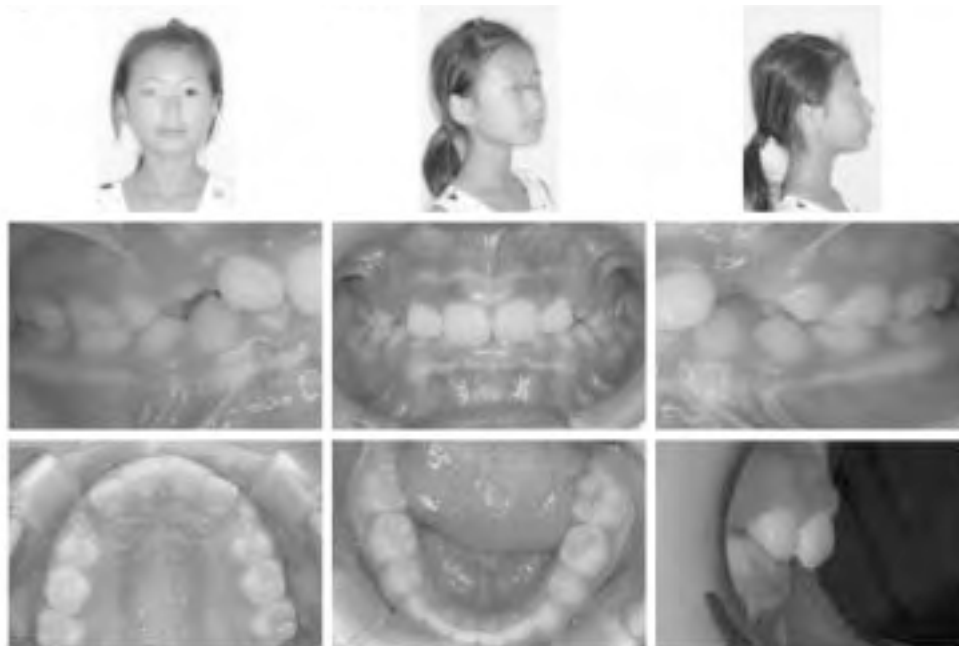

Fig. 29 Before Phase I treatment with T4K™ (age 9Y9M)

4) Application of functional orthodontic appliances to treatment of "mandibular retrusion syndrome"

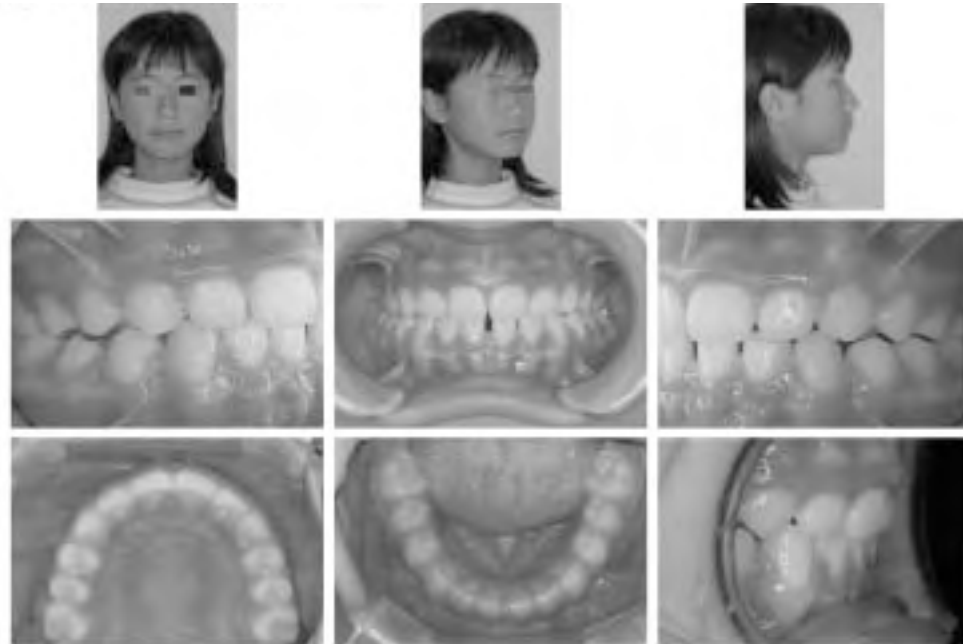


Fig. 30 After Phase I treatment with 1 year and 5 months of T4K™ (age 11Y2M)

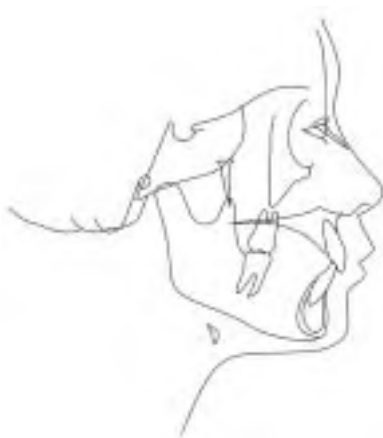

Fig. 31 Before Phase I (age 9Y9M)

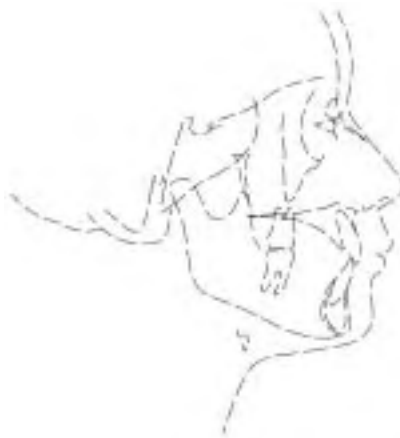
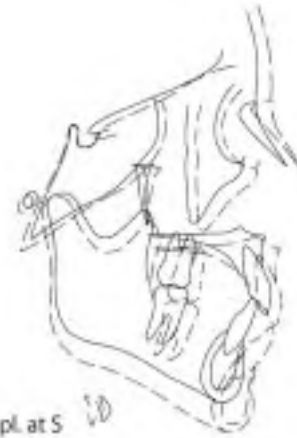
Fig. 32 After Phase I (age 11Y2M)



S-N pl. at S

Fig. 33 Changes after 1 year and 5 months of treatment

tomy was successfully performed 6 months into treatment. There were favorable changes in ANB and FMA to 4.4° and 21.3°, respectively. The lower inter-premolar width increased 4mm as measured on models.

**FEATURE: Maxillary protrusion**

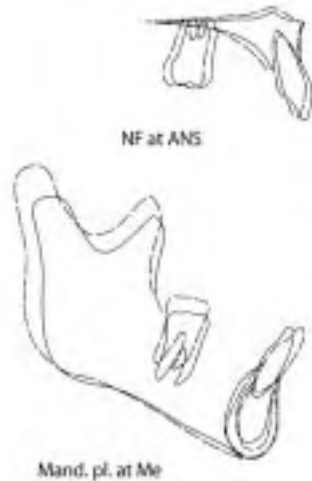

Fig. 34 Maxillary and mandibular changes

Fig. 35 Cephalometric changes

Case 3	Before Phase I treatment age 9Y9M	After Phase I treatment age 11Y2M
SNA	90.8°	86.6°
SNB	85.2°	82.1°
ANB	5.6°	4.4°
Mand.Plane	20.1°	21.3°
U-1 to FH plane	104.4°	103.6°
L-1 to Mand. Plane	103.4°	98.7°
Facial axis	96.3°	88.1°
A'-ptm'	49.0mm	49.2mm
Gn-Cd	102.9mm	108.4mm
Pog'-Go	73.5mm	76.0mm
Gd-Go	48.7mm	52.0mm

<Case 4 W.E. > (Fig. 37-44)

**Diagnosis:** A 7-year-10-month-old girl presented with a deep bite. Facial examination showed a retruded mandible, a protrusive upper lip, an everted lower lip and mentalis strain. Molar relationship was Class I on the left and Class II on the right. The upper anterior teeth were protrusive with an overjet of +5mm and overbite of +4mm. Surgical revision of a high upper labial frenum was needed. Cephalometrically, ANB was 5.2° with retruded B point. FMA was 35.0°. These data led to the diagnosis of a Class II division 1 malocclusion.

—End of Phase I: 1 year and 5 months of treatment time

The patient and parents felt that the teeth became nice and straight at the end of treatment with the T4K™. Facially, upper lip protrusion, lower lip curl and mentalis strain were eliminated with a reduction in retrusive appearance of the mandible. The molar relationship was still Class I on the left and Class II on the right. Both overjet and overbite were decreased to +1.0mm. The frenum attachment was released and repositioned 6 months into treatment and remains in good condition. ANB was reduced to 4.7° and FMA to 33.8°. Model analysis showed an increase of 4mm in upper inter-premolar width.

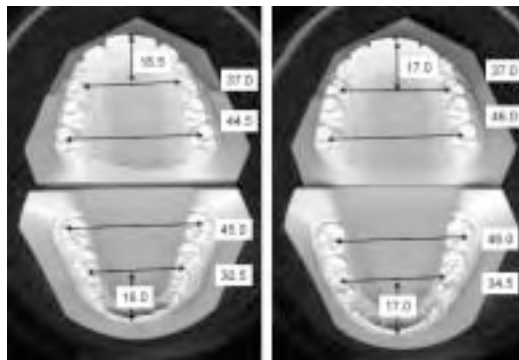


Fig. 36 Changes in upper and lower dental arches

**Discussion**

We were able to experience the effectiveness of the T4K™ through the cases we treated. The T4K™ is a prefabricated, single-sized appliance. Its most prominent feature is the ability to encourage proper use of the perioral muscles. The T4K™ helps to establish a natural occlusal relationship for each individual child and to form an unstrained pattern of chewing. Morphologically, it creates an environment conducive to proper perioral soft tis-

4) Application of functional orthodontic appliances to treatment of "mandibular retrusion syndrome"

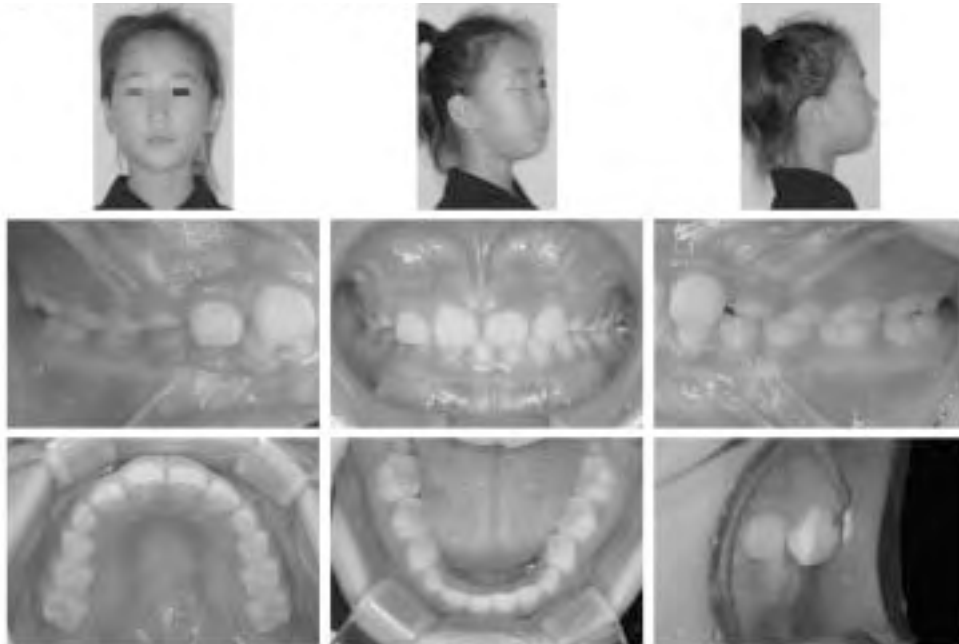

Fig. 37 Before Phase I treatment with T4K™ (age 7Y10M)

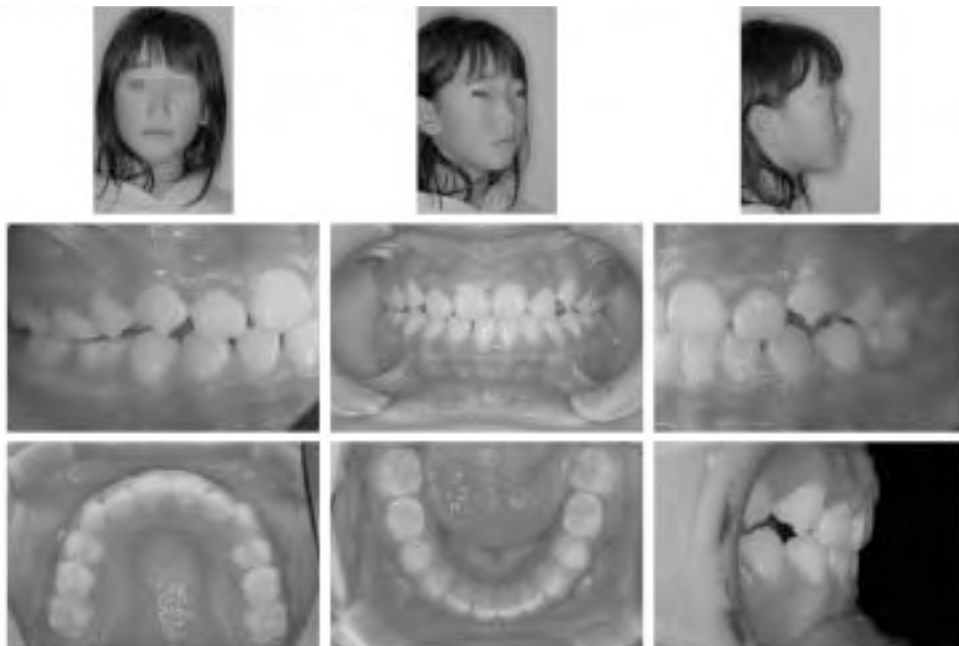

Fig. 38 After Phase I treatment with 1 year and 5 months of T4K™ (age 9Y3M)

**FEATURE: Maxillary protrusion**

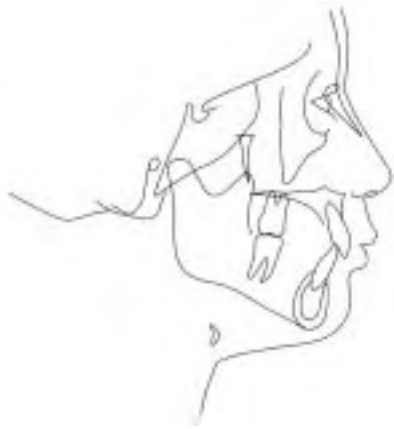

Fig. 39 Before Phase I (age 7Y10M)

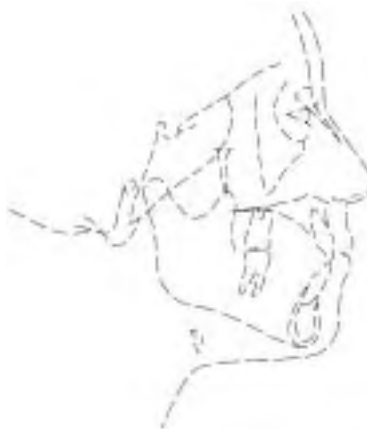

Fig. 40 After Phase I (age 9Y3M)

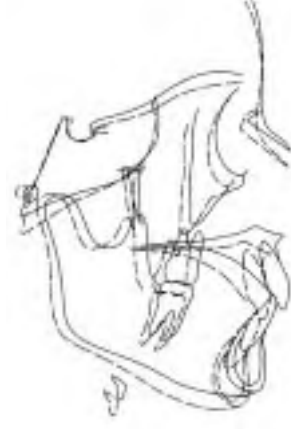

Fig. 41 Changes after 1 year and 5 months of treatment

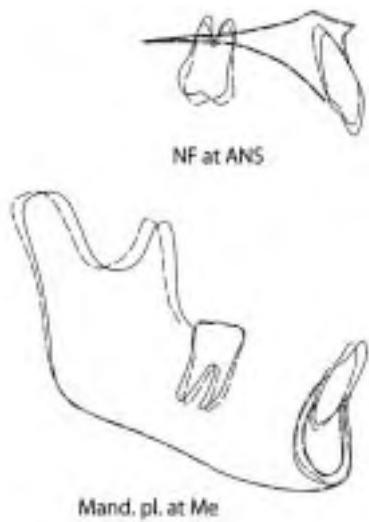


Fig. 42 Maxillary and mandibular changes

Fig. 43 Cephalometric changes

Case 4	Before Phase I treatment age 7Y10M	After Phase I treatment age 9Y3M
SNA	80.4°	79.8°
SNB	75.3°	75.0°
ANB	5.2°	4.7°
Mand.Plane	35.0°	33.8°
U-1 to FH plane	97.2°	96.3°
L-1 to Mand. Plane	88.5°	98.8°
Facial axis	71.8°	80.4°
A'-ptm'	43.7mm	45.5mm
Gn-Cd	101.6mm	107.8mm
Pog'-Go	68.6mm	76.9mm
Gd-Go	51.2mm	49.4mm

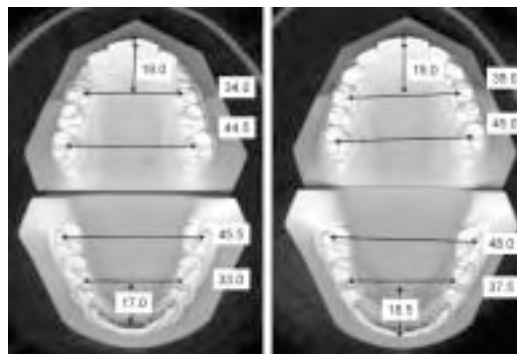


Fig. 44 Changes in upper and lower dental arches



sue movement and natural posture of the perioral muscles.

Our experience suggests that the T4K™ is as effective as Bionator or Twin Block, though it may not be as easy to wear. Hellman Dental age 3B, a period closer to mandibular growth peak, may be the most desirable time for functional appliance therapy. The T4K™ can be used effectively in Hellman Dental age 3B as well, for it enables eruption guidance of ectopic canines and premolars into the dental arch. This is difficult to accomplish with Bionator or Twin Block.

The T4K™ has an arch-expansion effect without an expansion screw. All cases presented in this paper showed arch width increases in the upper posterior area. The T4K™ applies expansive force to a narrower dental arch because of a difference in width between the appliance and the dental arch. In our experience, the T4K™ is also effective in developing the lower dental arch. For patients with severe arch deformities, prior treatment such as orthodontic alignment of anterior teeth and arch expansion with an expander may be needed before the use of the T4K™, as is the case for Bionator and Twin Block.

In the treatment of “mandibular retrusion syndrome”, the T4K™ works by guiding the mandible forward using the upper anterior teeth for anchorage. The upper tooth channel of the appliance is configured in such a way as to torque the crowns palatally, decreasing the labial inclination of the upper incisors. Proclination of the lower incisors may occur with the use of the appliance, though not observed in the present cases.

The mechanism of action of the T4K™ on the soft tissues is to encourage normal swallowing by bringing the anterior teeth into an edge-to-edge position and thereby facilitating lip seal. This action is common to other func-

1. Light tooth contact
2. Lip seal
3. Stable tongue posture
4. Nasal breathing

Fig. 45 Requirements for proper oral function at rest

tional appliances. In our view, proper oral function simply consists of light tooth contact, lip seal, stable tongue posture and nasal breathing (Fig. 45), yet there aren't many children equipped with all these elements. We even see many adults walking with the mouth open.

The posture of the perioral muscles is acquired and becomes a habit through repeated swallowing and breathing in infancy and early childhood<sup>13)</sup>. The optimal timing for myofunctional intervention is a period of active growth and development with high adaptive capacity<sup>14)</sup>. If the timing is missed, the child would acquire compensatory habits, which would require considerable efforts to correct later in life.

We regard morphological correction or normalization as a key to the establishment of normal function when mouth breathing and other myofunctional habits persist. As we continue to observe our growing patients, it is our hope to promote healthier growth through Phase I treatment with this objective in mind and by paying close attention to form and function.

### Summary

This paper introduced the mechanics of the the TRAINER System™ and clinical cases treated with the T4K™, demonstrating the effectiveness of the appliance in guiding the mandible forward and expanding the upper

and lower arches in maxillary protrusion cases with “mandibular retrusion syndrome” often seen among Japanese. When we first saw the appliance, we wondered if such a simple appliance would have any effect. However, many “mandibular retrusion syndrome” cases have been treated successfully with the T4K™ in our clinic. We would like to further increase our clinical experience with the TRAINER System™ and collect objective and scientific data to validate the theory behind and the treatment effect of the system. We also hope to gain a better, more accurate understanding of growth peak, which is the key to the success of Phase I treatment to produce a greater effect in a shorter period of time.

#### References

- 1) Maeda T, Imai R, Higuchi N, et al.: A study on eating function and behavior of children —Occlusal force and chewing force. *J Jap Soc Pediatr Dent.* 27; 1002-1009, 1989.
- 2) Okazaki M: Significance of chewing training in young children. *Pediatrics of Japan* 41: 2167-2175, 2000
- 3) Funakoshi M: *Patho-oral physiology.* Tokyo, Gakken Shoin, 112-132, 1990.
- 4) Nishida Y: Reevaluation of chewing function of the first molar. *J. Gifu Dent College* 16: 1-15, 1989.
- 5) Kerr J, McWilliam JS, Linder-Aronson S.: Mandibular form and position related to changed mode of breathing — a five-year longitudinal study. *Angle Orthod.* Summer; 59(2): 91-96, 1987
- 6) Schievano D, Rontani RMP, Berzin F.: Influence of myofunctional therapy on the perioral muscles. Clinical and electromyographic evaluations. *J. Oral rehab.* 26: 564-569, 1999.
- 7) Harvold EP, Tomer BS, Vargervik K, Chierici G.: Primate experiments on oral respiration. *Am J Orthod.* Apr; 79(4): 359-372, 1981.
- 8) Kataura A: An organ with two faces — Tonsil and its diseases. *Nanzando.* 97-99, 2005.
- 9) Kanao A: Application of T4K TRAINER to “mandibular retrusion syndrome”. *J Clin Pediatr Dent.* 12(9): 45-58, 2007.
- 10) Nezu H, et al.: Morphological classification of Class II malocclusions in Japanese in relation to Nasion-perpendicular (McNamara line). *J Jap Orthod Soc* 44: 749, 1985
- 11) Nezu H: *Kyouseishikagaku Bioprogressive Shindangaku.* Rocky Mountain Morita, 74, 2004.
- 12) Balters, W.: Ergebnis der gesteuerten Selbstheilung von kieferorthopädischen Anomalien, *Dtsch Zahnärztl* 15: 241-248, 1960.
- 13) Inoue N, Sakashita R: Dental health from infancy for the mouth and future of children. *Medi-Science,* 126-129, 1992.
- 14) Kin T: Easy child-care, finishing weaning at age 1 year. *Gendaishorin,* 57-69, 2004.
- 15) Myofunctional Research Co.: TRAINER SYSTEM™ DVD, 2008.